



Contents lists available at ScienceDirect

# Clinical Imaging

journal homepage: <http://www.clinicalimaging.org>



## Corrigendum

### Corrigendum to “The radiological findings of chordoid glioma: report of two cases, one case with MR spectroscopy” [*Clin Imaging* 39 (2015) 1086–1089]



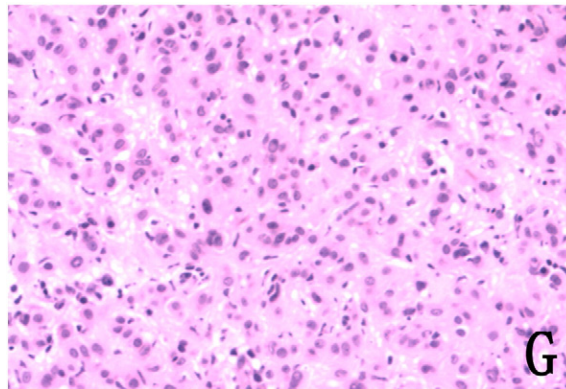
Feng Qixing<sup>a</sup>, Gao Peiyi<sup>a</sup>, Wang Kai<sup>a</sup>, Chen Xuzhu<sup>a</sup>, Min Xiangde<sup>b</sup>, Dai Jianping<sup>a,\*</sup>

<sup>a</sup> Department of Neuroimaging, Beijing Tiantan Hospital, Capital Medical University, Beijing, China

<sup>b</sup> Department of Radiology, Tongji Hospital, Tongji Medical College, Huazhong University of Science and Technology, Wuhan, Hubei 430030, China

The authors regret that the histological image of case 1 (Fig. 1G) is incorrect. The corrected version of Fig. 1G is shown below. The corrected image demonstrates the same findings as the original image.

The authors would like to apologize for any inconvenience caused.



DOI of original article: <http://dx.doi.org/10.1016/j.clinimag.2015.06.011>.

\* Corresponding author at: Department of Neuroimaging, Beijing Tiantan Hospital, Capital Medical University, Beijing, China.

E-mail addresses: [paper\\_connect@yeah.net](mailto:paper_connect@yeah.net), [ekkehard.hewer@pathology.unibe.ch](mailto:ekkehard.hewer@pathology.unibe.ch) (D. Jianping).

<http://dx.doi.org/10.1016/j.clinimag.2016.03.001>

0899-7071/© 2016 Elsevier Inc. All rights reserved.